



<b>Client</b>	Kevin S.	<b>Date of Incident</b>	03/01
<b>Defendant</b>	Mark Smith	<b>Victim(s)</b>	Michelle Carder

Medical Records Reviewed:

- Durham County Health Care Agency dated 03/22 to 06/24.
- UNM Healthcare dated 03/01 to 03/27.
- Western Medical Center 03/27, 04/17, and 06/16.

Additional Records Reviewed:

- Durham County Probation Department Probation & Sentencing Report dated 06/13
- Comprehensive Risk Assessment dated 07/23

## Initial Analysis Report

### Case Summary:

On 03/01, Mr. Mark Smith was brought to the emergency room at the Durham County Health Care Agency for multiple gunshot wounds to the abdomen, upper right chest, right arm, and right lower leg. During his treatment in the emergency room the physician had to cut his chest open and spread the ribs apart to due to the cardiac arrest he suffered.<sup>1</sup> Fortunately, he regained his own heart beat and was able to be further treated. He subsequently underwent intubation with a breathing tube due to respiratory distress/arrest and a chest tube to re-inflate the lung due to its collapse. A large central venous catheter was placed due to the massive amount of blood loss due to the gunshot wound to the brachial artery of the right arm. This catheter was required for rapid fluid/blood infusion due to the large blood loss volume. His initial diagnoses in the emergency room included: hemorrhagic shock from hemothorax, abdominal great vessel bleeding, upper extremity arterial bleed, or pelvic fracture.

*Case summary continues. It has been deleted from this sample report.*

---

<sup>1</sup> Appendix A, p. 1



*Sample report: names have been changed and portions have been deleted.*

Multiple injuries/diagnoses included:

- Open comminuted fracture of the right tibia - *Bone protruding through skin with multiple shattered bone fragments.*
- Fractured right fibula - *Broken lower leg bone.*
- Pelvic comminuted fractures - *Shattered pelvic bones.*
- Injury of right brachial artery with large amount of muscle destruction - *Upper arm artery damage.*
- Right humeral comminuted fractures - *Right upper arm shattered bone fragments.*
- Multiple intestinal injuries – *Abdominal injuries.*
- Hemorrhagic shock - *Shock due to loss of blood volume.*
- Respiratory failure - *Cessation of adequate breathing.*
- Necrosis of the small bowel - *Tissue death.*
- Urinary bladder rupture.
- Sacral decubitus stage 2 or 3 – *Skin ulcerations to tailbone area from pressure.*
- Multiple deep vein thrombosis - *Blood clots.*

Surgical procedures included:

- Temporary dialysis - *Removal of body waste to replace kidney's functions.*
- Placement of feeding tube – *Surgically placed in the stomach for feedings.*
- Abdominal exploration and re-exploration.
- Multiple serial abdominal closures.
- Pelvic exploration.
- Pelvic fracture repair.
- Bilateral chest tubes.
- Four compartment syndrome fasciotomies of right lower extremity – *Splitting open of muscle tissue to relieve pressure.*
- Closure of fasciotomies.
- External fixation of right lower extremity with hardware.
- Right lower extremity fixator adjustment.
- Removal of external fixator.
- Placement of wound VAC's - Vacuum type device to promote healing of tissue.

Current medications include:

- Tramadol: Pain medication for moderate to severe pain and is classified under the opiates.
- Dulcolax: Stimulant laxative.
- Calcium Carbonate: Calcium supplement.
- Norvasc: Hypertension.



*Sample report: names have been changed and portions have been deleted.*

## Summary of Health Status:

Mr. Smith endured hospitalization for approximately one month due to severe injuries from multiple gunshot wounds. He underwent multiple surgeries to repair his injuries and developed further medical issues due to the prolonged hospitalization. He has undergone intense physical, occupational and speech therapy to have progressed to his current health status. Mr. Smith still suffers from current medical issues.

### Nephrostomy Tubes

Mr. Smith is currently burdened with bilateral nephrostomy tubes. Due to the damage he suffered from the gunshot wounds to the abdomen and pelvis, the tubes that connect the kidney to the bladder were destroyed and had to be cut. Subsequently, he had to undergo the placement of the nephrostomy tubes that come from the kidney, out of the skin, and drain into an outside bag that is usually attached to the leg.

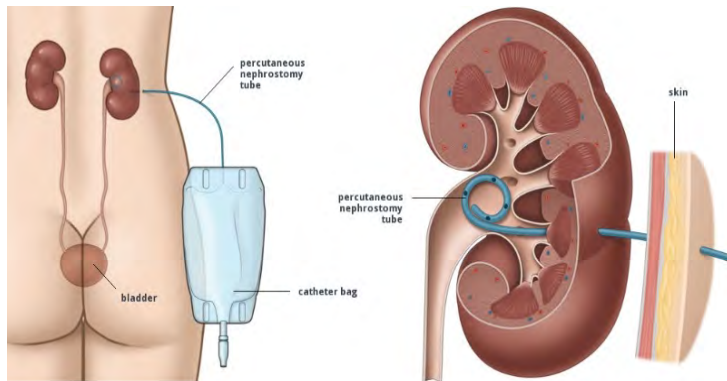


Figure 1 (European Association of Urology)

The continuous care with dressing changes and monitoring of these nephrostomy tubes is crucial as they can occasionally become dislodged and kinked. Some of the other issues that can occur are skin rash at the site of insertion, leakage of urine around the site of insertion, and pain which may be due to infection or migration of the tube (University of Virginia, 2013).

*Summary continues. It has been deleted from this sample report.*

## Summary of Opinions:

Mr. Smith has undergone severe and traumatic events due to the gunshot wounds and subsequent surgeries. Mr. Smith's current injuries and conditions will likely cause deterioration in his physical health as he ages, which will greatly increase his morbidity and mortality. He is likely to become debilitated with the injuries he has suffered in his right arm, right leg, and pelvis leading to a complete loss of mobility and become fully dependent for care. Mr. Smith currently relies on jail staff to assist him with the care and maintenance of his nephrostomy tubes and his colostomy and will potentially become increasingly dependent as he ages.



*Sample report: names have been changed and portions have been deleted.*

It is my opinion that Mr. Smith will require significant assistance with his daily care with frequent medical monitoring of his colostomy and bilateral nephrostomy tubes which may be difficult while incarcerated. Mr. Smith currently relies on medical staff in the jail in relation to his colostomy care as well as his nephrostomy tubes, as the dressings and supplies for both need to be changed on a frequent basis. Medical management and continuous assessment of the colostomy and nephrostomy tubes is required to ensure patency and health of the devices. Mr. Smith will also require recommended nephrostomy tube changes every three or four months.<sup>2</sup>

Mr. Smith will require extensive resources from the prison system due to the physical issues he currently suffers from. The constant medical care and attention from the prison medical staff, along with the medical supplies that are required to care for Mr. Smith's colostomy and nephrostomy tubes, will place a financial burden on the facility. He will also require increased medical care and interventions when he requires his nephrostomy tubes changed. Services will further be required to transport Mr. Smith to and from the prison for his follow up medical care.

With all of the medical issues that Mr. Smith has endured, his prognosis may be limited. Due to the potential for lead intoxication and his limited mobility, Mr. Smith is at high risk for systemic infections and organ failure. His chronic pain places him at risk for depression, which is associated with a multitude of other complications; such as opiate addiction, suicidality, and an overall poor recovery rate.

The opinions in this report are within a reasonable degree of medical certainty based upon the documentation provided and referenced within this report. However, I reserve the right to amend my opinions upon receipt of additional information.

Thank you for the opportunity to work with you on this case. Please don't hesitate to contact me if you have any questions or concerns.

## **Works Cited**

- Abraham, A., Singh, J., Mustacchia, P., & Rizvon, K. (2012, May 08). *Pain from a bullet lingers on: An uncommon case of lead toxicity*. Retrieved from National Institutes of Health: <http://www.ncbi.nlm.nih.gov/pmc/articles/PMC3369416/>
- Fischer, M. (N.D.). *Lesson 3, Unit 19*. Retrieved from We Care Online : <http://www.wecareonlineclasses.com/nurseaideebuild/new%20regs/unit%203/section7.html>
- University of Virginia. (2013, February 14). *Nephrostomy Tube*. Retrieved from University of Virginia School of Medicine : [http://www.medicine.virginia.edu/clinical/departments/radiology/Patients\\_and\\_Visitors/radiology-exams/nephrostomy-tube](http://www.medicine.virginia.edu/clinical/departments/radiology/Patients_and_Visitors/radiology-exams/nephrostomy-tube)

---

<sup>2</sup> Appendix A, p. 4